

Membranous Congenital Cataract With Partial Absorption in Congenital Rubella Syndrome

NMA Surasmiati, Luh S Maharani, Komang D Lestari,
 IWE Sutyawan, IWG Jayanegara
 Ophthalmology Department Udayana University/Sanglah Hospital,
 Denpasar-Bali

Purpose
 Congenital Rubella Syndrome (CRS) is a condition due to maternal rubella virus infection. Rubella infection has an extensive manifestation of both the eye and systemic. Cataract is one of the most frequent manifestation of CRS, although membranous cataract and its absorption are rare. We report a case of CRS presenting membranous cataract which partially absorbed at the time of presentation.

Methods
 A case reports of 5 months old boy present with nystagmus, microcornea, leukocoria, pinpoint pupils with negative pupil reflexes, and the USG examination supports the existence of a lens with membranous echo and microphthalmia. We planned evaluation under anesthesia, followed by pupiloplasty, and cataract extraction

Result
 Examination under anesthesia revealed a membranous cataract with partial absorption. Pupiloplasty and cataract extraction were done. Follow up examination showed esotropia which indicate an amblyopia. Management continued with spectacles to prevent futher amblyopia.

Conclusion
 Cataract in CRS can manifest as a membranous form due to its partial absorption. Surgical procedure of the cataract, although is very challenging, followed by visual rehabilitation will help to achieve a better visual outcome

Keywords
 Congenital Rubella Syndrome, Membranous Cataract, Partial Absorption

We acknowledge Prof Rita S Sitorus, MD, PhD for her valuable input to this paper

References

1. American Academy of Ophthalmology Staff. 2014-2015. Fundamentals and Principles of Ophthalmology Sec 2 San Francisco: AAO. p 117-21
2. Babichayev MA, et al. 2014. Studies on The Cornea and Lens. New York: Springer Humana Press p 436-37
3. Lin Hsueh, et al. 2014. Congenital Cataract Prevalence and Surgery Age at ZOC. PLOS one Vol 9
4. Long Jing, et al. 2017. Clinical Characteristic and Surgical Procedure for Children with Congenital Membranous Cataract. Hindawi.
5. Lorencu C, Dascaliescu D, et al. 2016. Romanian Journal of Ophthalmology Vol 60(1). p 37-39
6. Messina BO, Cuevas SA. 2017. Inherited Congenital Cataract Mexico: Mol Syndrom Vol 8 p 58-78
7. Medungu, Nauchal KK. 2015. Pediatric Cataract: challenges and future directions. Clin Ophth. Vol 9
8. Zang ZD, et al. 2010. Congenital membranous cataract assoc with PFV. China J O. Vol 3(4)

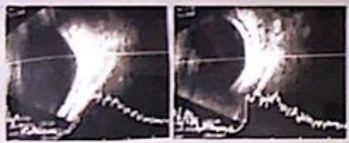


Figure 1. USG right and left eyes

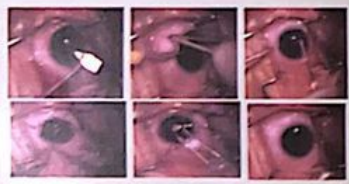


Figure 2. Pupiloplasty and cataract extraction procedure

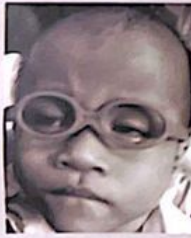

Figure 3. Patient with aphakic glasses following cataract surgery

APSPoS TRAVEL GRANT



IS AWARDED

TO


Dr. Ni Made A. SURASMIATI

AT

INAUGURAL ASIA-PACIFIC STRABISMUS AND PAEDIATRIC
 OPHTHALMOLOGY SOCIETY (APSPoS) CONGRESS
 HELD IN CONJUNCTION WITH
 THE INAUGURAL HONG KONG PAEDIATRIC
 OPHTHALMOLOGY CONGRESS (APSPoS-HKPOC 2017)


 Prof. Frank Martin
 President

OCTOBER 11, 2017
 DATE



Ni Made Ayu Surasmiati
(Indonesia)

